


PATIENT PRESENTING CLINICAL SIGNS

Cooper Trewinnard

History: Hyporexia, intermittent GI signs.

SPECIES

Feline

Physical Examination: Asymmetric kidneys, possible abdominal mass.

Urinalysis: N/A.

CBC: N/A.

BREED

DSH

Serum Biochemistry: N/A.

Radiographic Findings: N/A.

SEX

MN

Age

16 years

ULTRASONOGRAPHIC EXAMINATION OF THE ABDOMEN
Urinary System

Full urinary bladder with a normal thickness and appearance of the wall. Small amount of floating hyperechogenic sediment present. No uroliths evident.

WEIGHT

4.55 kg

Normal trigone area, proximal urethra, and iliac blood vessels.

Normal iliac lymph nodes (0.2 cm). Ureters not visualized.

INTERPRETED BY

 Remo Lobetti, BVSc,
MMedVet (Med), PhD, Dipl.
ECVIM

Small left kidney (2.2 cm), enlarged right kidney (5.3 cm) both with a hyperechogenic appearance, loss of cortico-medullary differentiation, and normal pelvis and capsule.

Reproductive System

N/A.

IMAGING PERFORMED BY

Dr Sarah Barthelemy

Adrenal Glands

Normal position, echogenic appearance, shape, and size. Left 0.38 cm, right 0.33 cm.

HOSPITAL NAME

Alpine 24 Hour Pet Hospital

Spleen

Enlarged (1.2 cm) with a diffuse increased echogenic appearance. Smooth homogenous parenchyma, regular curvilinear capsule, and normal vasculature. No evidence of inflammatory, neoplastic, infarction, or infiltrative changes noted.

REFERRING VET

Dr Nielsen

Liver

Normal size, echogenic appearance, portal markings, and regular curvilinear capsule. No nodules or masses evident. Full gall bladder containing normal anechoic bile. Normal thickness and echogenic appearance of the gall bladder wall. Normal bile duct.

INVOICE

303768

Gastrointestinal
DATE

1/14/23

Normal appearance of the stomach, ileo-cecal junction, and colon with no loss of layering, normal wall thickness and peristalsis, and no distension of the lumen. Generalized thickening of the muscularis layer of the duodenum and small intestine with no loss of layering or distension of the lumen.

**PATIENT** *Pancreas*

Cooper Trewinnard

Normal size (left 0.8 cm) with a hypoechogenic appearance, visible pancreatic duct, and irregular capsule. Hyperechogenic appearance of the mesentery and fat surrounding the pancreas.

SPECIES *Free Abdomen*

Feline

Mesenteric lymphadenomegaly with a rounded and hyperechogenic appearance.
No ascites.

BREED

DSH

ULTRASONOGRAPHIC FINDINGS**SEX**

Primary Findings:

MN

- Splenomegaly.
- Right renomegaly.
- Lymphadenomegaly.
- Pancreatitis.
- Enteropathy.

Age

16 years

WEIGHT

4.55 kg

Secondary Findings:

- Urinary bladder sediment.

INTERPRETED BY

Remo Lobetti, BVSc,
MMedVet (Med), PhD, Dipl.
ECVIM

INTERPRETATION OF THE FINDINGS & FURTHER RECOMMENDATIONS

With the appearance of the spleen, kidneys, and lymph nodes, the most likely diagnosis would be lymphoma with granulomatous disease a differential diagnosis.

IMAGING PERFORMED BY

Dr Sarah Barthelemy

The appearance of the pancreas is typical for pancreatia.

Etiologies for the enteropathy would be inflammatory bowel disease, parasitic enteritis, dietary hypersensitivity, granulomatous disease, and lymphoma.

HOSPITAL NAME

Alpine 24 Hour Pet Hospital

Further assessment would be fecal analysis, serum biochemistry, fPL/PSL assay, FNA cytology of the spleen and lymph nodes, and possibly endoscopy of the upper GI tract with biopsies.

REFERRING VET

Dr Nielsen

Specific therapy would be dependent on an etiological diagnosis.

INVOICE

303768

DATE

1/14/23



PATIENT

Cooper Trewinnard

SPECIES

Feline

BREED

DSH

SEX

MN

Age

16 years

WEIGHT

4.55 kg

INTERPRETED BY

Remo Lobetti, BVSc,
 MMedVet (Med), PhD, Dipl.
 ECVIM

IMAGING PERFORMED BY

Dr Sarah Barthelemy

HOSPITAL NAME

Alpine 24 Hour Pet Hospital

REFERRING VET

Dr Nielsen

INVOICE

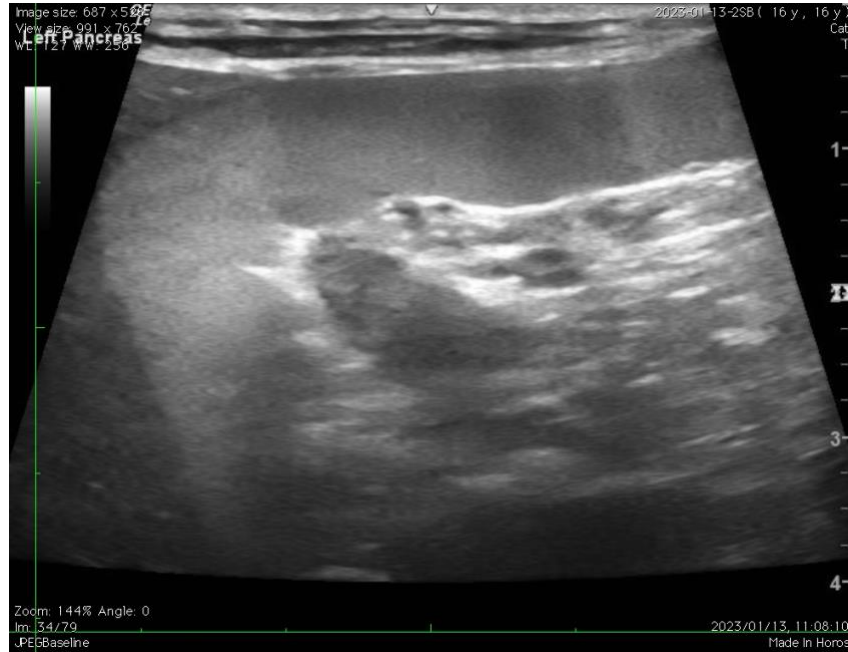
303768

DATE

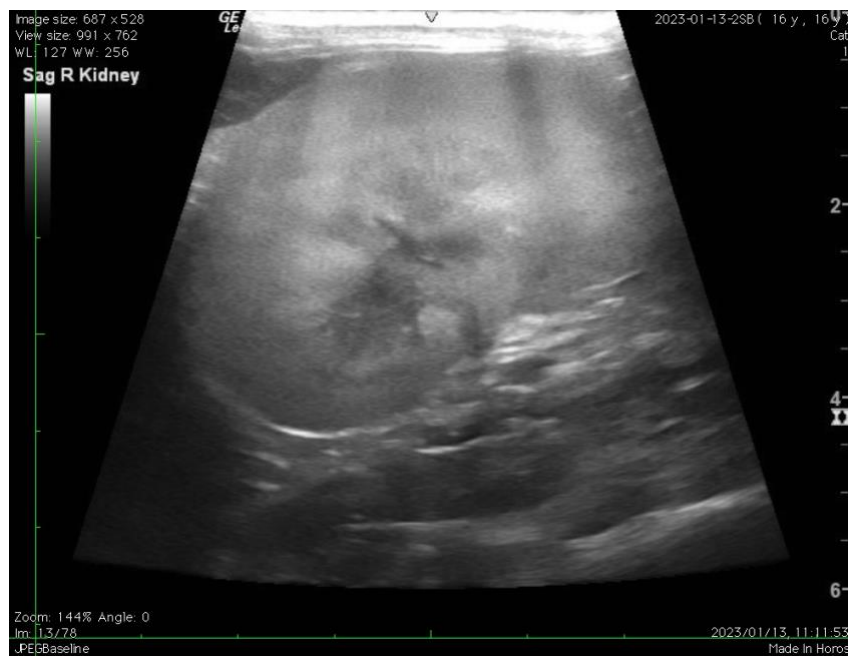1/14/23

IMAGES

Spleen



Right kidney





PATIENT

Duodenum

Cooper Trewinnard

SPECIES

Feline

BREED

DSH

SEX

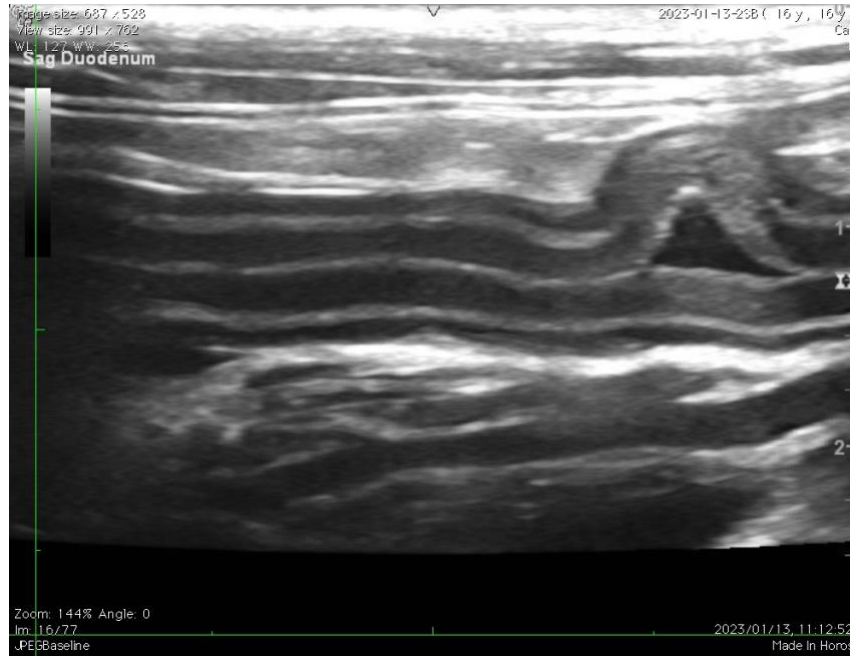MN

Age

16 years

WEIGHT

4.55 kg



INTERPRETED BY

Lymph node

Remo Lobetti, BVSc,
 MMedVet (Med), PhD, Dipl.
 ECVIM

IMAGING PERFORMED BY

Dr Sarah Barthelemy

HOSPITAL NAME

Alpine 24 Hour Pet Hospital

REFERRING VET

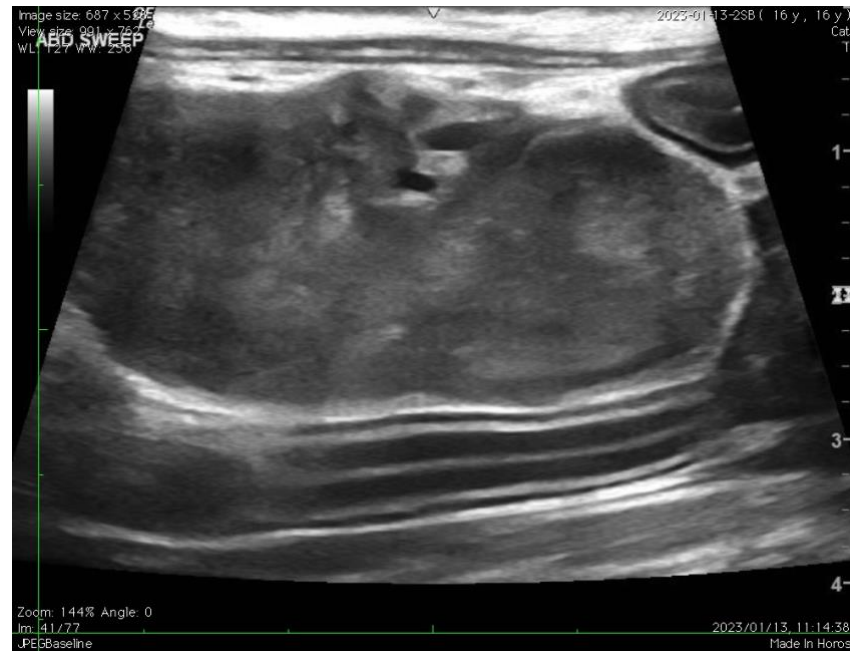Dr Nielsen

INVOICE

303768

DATE

1/14/23





PATIENT Pancreas

Cooper Trewinnard

SPECIES

Feline

BREED

DSH

SEX

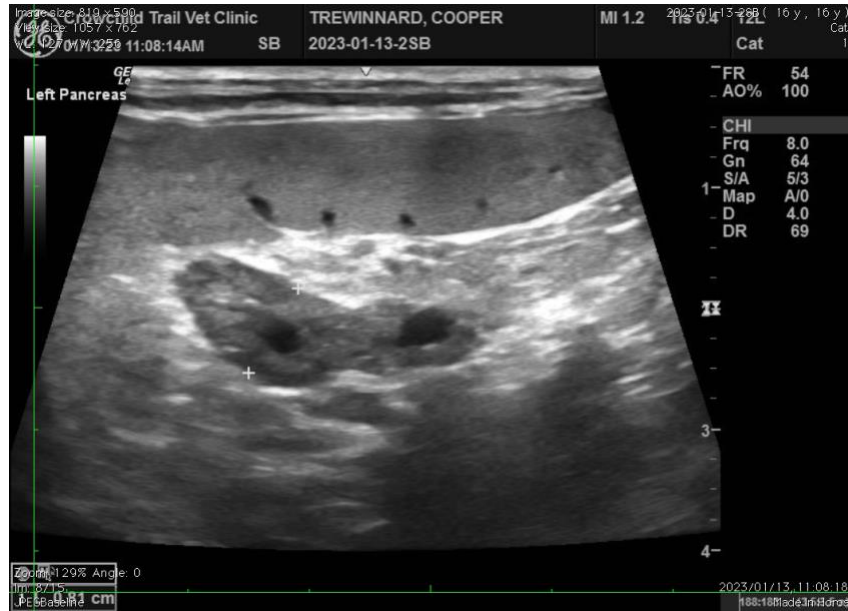MN

Age

16 years

WEIGHT

4.55 kg



INTERPRETED BY

Remo Lobetti, BVSc,
 MMedVet (Med), PhD, Dipl.
 ECVIM

The information and recommendations provided are based on the images presented by the referring veterinarian. No evaluation can be communicated regarding pathology that was not visible in the image/video clips provided.

Thank you for this referral. If the clinical or image interpretation does not parallel your findings or if I can be of any further assistance, please contact me.

IMAGING PERFORMED BY

Dr Sarah Barthelemy

Remo Lobetti, BVSc, MMedVet (Med), PhD, Dipl. ECVIM (Internal Medicine)
rlobetti@mweb.co.za

HOSPITAL NAME

Alpine 24 Hour Pet Hospital

REFERRING VET

Dr Nielsen

INVOICE

303768

DATE

1/14/23